

Photochemical Dermatitis Due to Contact With Sosnovsky Hogweed

A.Yu. Simonova*, M.V. Belova, K.K. Ilyashenko, N.E. Pidchenko, M.M. Potkhveriya, A.V. Sachkov, I.N. Ponomarev

Department of Acute Poisoning and Somatopsychiatric Disorders
N.V. Sklifosovsky Research Institute for Emergency Medicine of the Moscow Healthcare
Department 3 B. Sukharevskaya Sq., Moscow 129090, Russian Federation

* **Contacts:** Anastasia Yurievna Simonova, Candidate of Medical Sciences, Leading Researcher of the Department of Acute Poisoning and Somatopsychiatric Disorders, N.V. Sklifosovsky Research Institute for Emergency Medicine. Email: simonovatoxy@mail.ru

INTRODUCTION Today, the spread of the Sosnovsky hogweed plant has acquired an unprecedented scale, which is accompanied by an annual increase in the number of victims due to the occurrence of photochemical dermatitis (PD).

AIM OF STUDY To study the clinical picture of PD arising in patients as a result of contact with Sosnovsky hogweed juice, to develop measures for their prevention and treatment.

MATERIAL AND METHODS The study involved 139 patients with a diagnosis of photochemical dermatitis who were treated in the department of acute poisoning and somatopsychiatric disorders of the N.V. Sklifosovsky Research Institute for Emergency Medicine.

RESULTS All patients had skin lesions of varying prevalence, more often the upper and lower extremities, similar in depth to superficial thermal burns of I, II, IIIA degrees.

CONCLUSIONS The complex of treatment for patients should include detoxification, antihistamine, analgesic, hormonal, antibacterial therapy, as well as local treatment carried out by combustiologists.

Keywords: photochemical dermatitis, Sosnovsky hogweed, treatment

For citation Simonova AY, Belova MV, Ilyashenko KK, Pidchenko NE, Potkhveriya MM, Sachkov AV, et al. Photochemical Dermatitis Due to Contact With Sosnovsky Hogweed. *Russian Sklifosovsky Journal of Emergency Medical Care*. 2020;9(4):653–658. <https://doi.org/10.23934/2223-9022-2020-9-4-653-658> (in Russ.)

Conflict of interest Authors declare lack of the conflicts of interests

Acknowledgments, sponsorship The study had no sponsorship
Affiliations

Anastasia Yu. Simonova	Candidate of Medical Sciences, Leading Researcher of the Department of Acute Poisoning and Somatopsychiatric Disorders, N.V. Sklifosovsky Research Institute for Emergency Medicine; https://orcid.org/0000-0003-4736-1068 , simonovatoxy@mail.ru 30%, analysis and interpretation of data, analysis of literature, preparation of the article text
Maria V. Belova	Doctor of Biological Sciences, Leading Researcher of the Department of Acute Poisoning and Somatopsychiatric Disorders, N.V. Sklifosovsky Research Institute for Emergency Medicine; https://orcid.org/0000-0002-0861-5945 , manibel@gmail.ru ; 20%, technical processing and description of data, preparation of the article text
Nikita E. Pidchenko	Surgeon of the Department of Acute Thermal Injuries, N.V. Sklifosovsky Research Institute for Emergency Medicine; https://orcid.org/0000-0002-5890-1800 , pidchenkone@gmail.com ; 10%, patient selection and treatment, data analysis
Mikhail M. Potkhveriya	Candidate of Medical Sciences, Head of the Department of Acute Poisoning and Somatopsychiatric Disorders, N.V. Sklifosovsky Research Institute for Emergency Medicine; https://orcid.org/0000-0003-0117-8663 , potkhveriya@mail.ru ; 10%, development of research design, participation in the analysis of results
Kapitalina K. Ilyashenko	Doctor of Medical Sciences, Professor, Scientific Consultant of the Department of Acute Poisoning and Somatopsychiatric Disorders, N.V. Sklifosovsky Research Institute for Emergency Medicine; https://orcid.org/0000-0001-6137-8961 , toxikapa@mail.ru ; 15%, participation in the analysis of results, preparation of the text of the article
Alexey V. Sachkov	Candidate of Medical Sciences, Head of the Scientific Department of Acute Thermal Injuries, N.V. Sklifosovsky Research Institute for Emergency Medicine; https://orcid.org/0000-0003-3742-6374 , hand@mail.ru ; 10%, data analysis, preparation of the article text
Ivan N. Ponomarev	Candidate of Medical Sciences, Researcher of the Department of Biotechnology and Transfusiology, N.V. Sklifosovsky Research Institute for Emergency Medicine; https://orcid.org/0000-0002-2523-6939 , rzam@yandex.ru ; 5%, patient selection and treatment

BACKGROUND

The rapid growth of giant hogweed of the *Heracleum* genus is currently a serious problem in Russia and in many European countries. This process has a negative impact on the biodiversity of the vegetation cover, destroying natural ecosystems, causing significant economic damage and posing a threat to human health [1–5].

The most aggressive representative of the genus *Heracleum* is the Sosnovsky hogweed (*Heracleum sosnowskyi*) - a giant umbrella weed plant, which began to be grown as a forage crop in the middle of the 20th century. Subsequently, thanks to its ability to self-seeding, it began to spread beyond agricultural land intensively. Currently, the expansion of this invasive plant is assuming the scale of an ecological disaster. Sosnovsky's hogweed has mastered the territories of Eastern Europe and practically the entire European part of Russia [6–12].

Isolated reports of the toxic effect of Sosnovsky's hogweed began to appear in the early years of the plant's introduction into agricultural production. Potentially toxic substances furanocoumarins (bergapten, isobergapten, isopimpinelin, xanthotoxin, psoralen, etc.) were found in its juice, causing damage to the skin. A number of publications have indicated that furanocoumarins, especially bergapten, have photosensitizing properties and, upon contact with

the skin, dramatically increase its sensitivity to ultraviolet radiation, causing skin damage similar to thermal damage [13–15].

Despite the fact that the pathogenic properties of Sosnowsky's hogweed have been known for many years, in the summer months victims refer to various specialists annually (toxicologists, combustiologists, dermatologists, therapists, etc.) after contact with this plant. This problem has become especially urgent for clinicians recently, when the spread of Sosnowsky's hogweed has acquired a large-scale character.

Modern scientific literature, the media and numerous Internet sites contain information on the control of the spread of Sosnowsky's hogweed and methods of combating it [16, 17]. However, there are not enough materials to study the effect of this plant on the body. On the basis of isolated publications describing individual clinical observations, it is difficult to form a unified idea of the clinical manifestations and treatment of skin lesions that occur after contact with Sosnowsky hogweed juice [13–15, 18, 19]. There is an opinion that these lesions, taking into account the pathogenesis of development, are photochemical dermatitis (PD) [20].

Currently, no clinical guidelines have been found for the diagnosis and treatment of PD caused by the contact with Sosnowsky's hogweed.

Aim of study: to study the clinical picture of FD, arising in patients as a result of contact with Sosnovsky hogweed juice, to develop measures for their prevention and treatment.

MATERIAL AND METHODS

The material of the retrospective study was the data of the annual reports of the Department of Acute Poisoning and Somatopsychic Disorders of N.V. Sklifosovsky Research Institute for Emergency Medicine from 2012 to 2019. We examined 139 patients who were treated in the Department of Acute Poisoning and Somatopsychic Disorders of N.V. Sklifosovsky Research Institute for Emergency Medicine during this period. Of those who applied for medical care within the specified time after contact with the juice of the Sosnowsky hogweed, 42 patients refused inpatient treatment. Fig. 1 shows the dynamics of the number of hospitalized patients over the years. The data obtained indicate that by 2015 the number of patients with PD decreased, their growth has been observed recently.

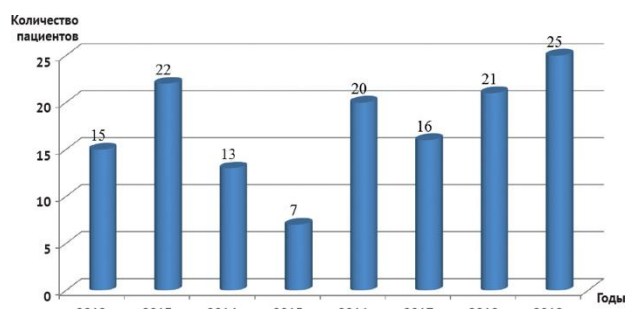


Fig. 1. Dynamics of the number of hospitalized patients with photochemical dermatitis after contact with hogweed juice in 2012–2019

Among hospitalized patients, there were 107 male patients (77%) and 32 (23%) female patients. The age of the patients ranged from 18 to 65 years, with the main share of the victims being in the age group 18–44 years (45.7%).

Patients sought medical attention from May to September with the highest frequency in June and July. It was found that in all cases the contact was of an accidental nature (mowing the plant, rest). It should be noted that skin lesions occurred after contact with hogweed juice, mainly in sunny weather. However, in a number of cases, the development of PD was observed after contact with the plant and in cloudy weather. In our opinion, it was associated with the individual sensitivity of patients to hogweed juice. In some patients, skin lesions developed after exposure to plant juice, even through the thin fabric of clothing. Direct contact with the plant was often unnoticed by patients, since it did not cause painful and unpleasant sensations.

It was found that the majority of victims (61%) sought medical help 1–2 days after contact with hogweed juice when the first symptoms of PD appeared. This was probably facilitated by the widespread coverage of this issue in the media recently. At the same time, it should be noted that, on average, 9.5% of patients sought medical help at the toxicology department on the 9–10th day, as a rule, already when complications occurred after self-medication.

The examination of the patients included examination by a toxicologist and combustiologist, general clinical and biochemical blood tests. The severity of the condition was assessed by the manifestations of intoxication, as well as by the area and depth of local lesions of the skin according to the classification of thermal burns (adopted at the XXVII All-Union Congress of Surgeons in 1961).

RESULTS

After contact with hogweed juice, all the victims had PDs of various prevalence, which manifested as desquamation of the epidermis and the formation of painful wounds similar in depth to thermal burns of I, II, IIIA degrees.

The analysis of the data obtained showed that for the period 2012–2019 of the total number of examined patients, 12 (8.6%) were hospitalized in the intensive care unit. In these patients, the lesion area averaged 20–35%, and the depth in different areas of the skin corresponded to grade II, IIIA burns. And 127 patients (91.4%) with an area of skin lesions from 2% to 20% of the body surface without intoxication were admitted to the Department for the Treatment of Acute Poisoning.

Upper and lower extremities were involved most often, then - the anterior and posterior surfaces of the body, head and neck (Fig. 2).

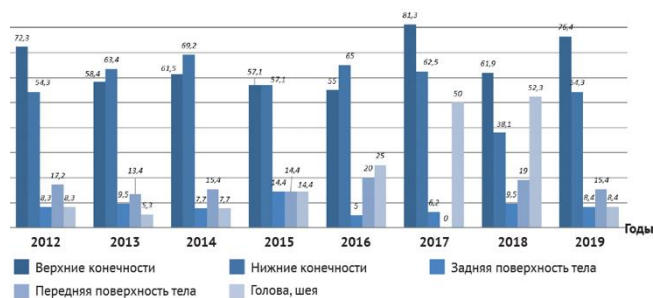

Fig. 2. Location of skin lesions in patients with photochemical dermatitis due to contact with hogweed juice

The first signs of local skin lesions did not appear immediately, but several hours or even 2 days after contact with the plant juice. According to the patients, at first there was skin hyperemia with clear boundaries, then small thin-walled blisters appeared, which subsequently merged into large blisters (Fig. 3). This was accompanied by significant edema of the surrounding tissues. The blisters were tense, thick-walled, filled with transparent serous contents (Fig. 4). It should be noted that in the presence of preserved blisters, the patients did not notice painful sensations; subsequently, when their integrity was violated, severe pains appeared, increasing when touching the wound, which was accompanied by itching and burning. It is noteworthy that the formation of bubbles occurred over several days, and not all at once. Along with this, some patients noted headache and dizziness.

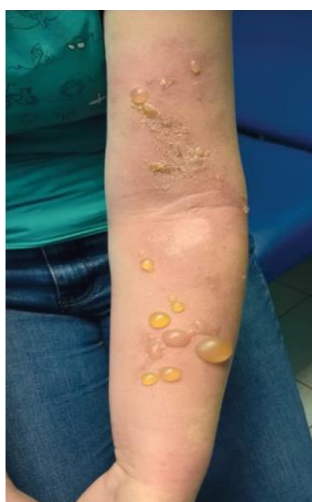

Fig. 3. A 28-year-old female patient P., 2nd day after contact with hogweed juice

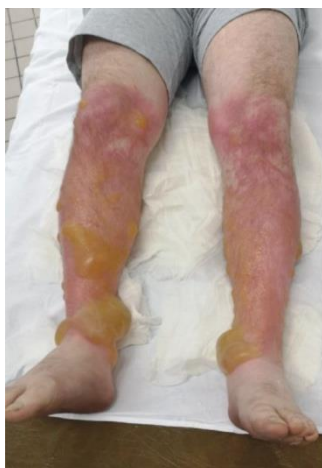

Fig. 4. A 25-year-old male patient V., 2nd day after contact with hogweed juice

In 11 patients who self-medicated at home and sought medical help on the 6-10th day after contact with hogweed juice, purulent-necrotic complications were observed during the wound process, which was manifested by erosion of surfaces, serous-purulent discharge and areas of thin dry necrosis (Fig. 5). Patients in this group had significant manifestations of intoxication (hyperthermia, headache, dizziness, chills, moderate leukocytosis).

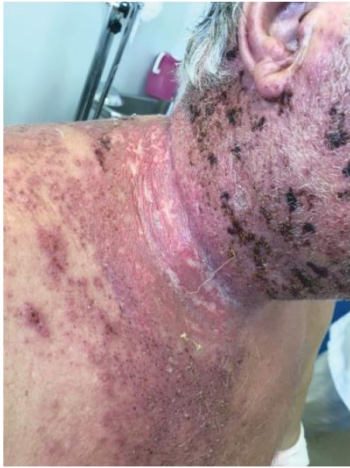

Fig. 5. A 65-year-old male patient S., 5th day after contact with hogweed juice during treatment

Upon admission to the hospital, all for patients with PD painkillers, antihistamines were prescribed, and hormones were administered if indicated. The volume of infusion therapy and its duration were determined depending on the degree of intoxication. For patients with signs of wound infection antibacterial drugs were indicated.

Local treatment of the affected skin areas was carried out by combustiologists using methods similar to the algorithms for treating thermal burns. Upon admission to the hospital, the patients underwent primary surgical treatment of wounds, which type and volume depended on the area and depth of the lesion. An aqueous solution of an antiseptic was used, the desquamated epidermis, epidermal blisters and their contents were removed. Conservative wound management included the use of atraumatic wound dressings. In the presence of areas of hyperemia, in order to relieve aseptic inflammation and prevent further desquamation of the epidermis, glucocorticoid-based ointments (triamcinolone, betamethasone) were used. Dressings were performed every 2–3 days. For inflammation and infection of wounds, water-soluble antimicrobial ointments based on chloramphenicol were used until they were completely healed. The local treatment allowed to avoid deepening wounds and surgical treatment.

On the 5-7th day, in the absence of wound infection, after a complex of local treatment, edema decreased, and active independent marginal and insular epithelialization was observed (Fig. 6, 7). In 11 patients, with the development of purulent-necrotic complications, spontaneous healing occurred by secondary intention on average on the 14-18th day.

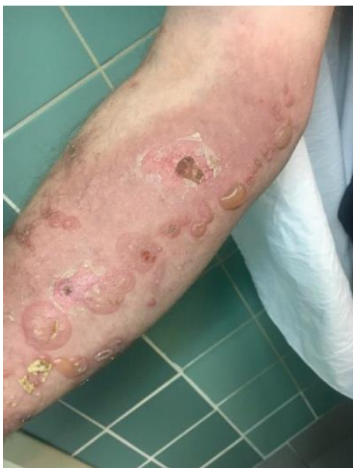

Fig. 6. A 34-year-old male patient V., 3rd day after contact with hogweed juice

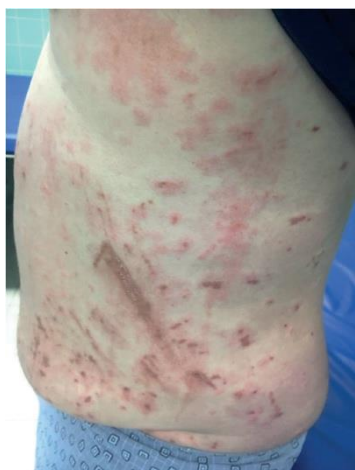

Fig. 7. A 55-year-old male patient T., 4th day after contact with hogweed juice during treatment

In all patients, dark pigmented areas remained at the sites of healed lesions.

Based on the analysis of domestic literature data and many years of our own experience, recommendations were developed for patients to prevent the development of PD due to contact with hogweed juice.

1. After contact with hogweed juice, the irritant should be immediately removed by rinsing the affected skin areas abundantly with running water and soap, using a soft sponge (if possible, take a shower). If hogweed juice gets into your eyes, rinse immediately with plenty of water for 15–20 minutes, if it gets into the mouth, rinse your mouth.
2. It is necessary to exclude insolation for 2-3 days.
3. If the moment of contact with hogweed juice is missed but hyperemia and blisters appeared, it is necessary to rinse the affected areas abundantly with water, treat them with an antiseptic solution, apply a sterile bandage, take an antihistamine and seek medical help - regardless of the area of the lesion and the severity of the manifestations of dermatitis.

CONCLUSION

1. All victims after contact with hogweed juice have photochemical dermatitis, manifested by lesions of the skin, in depth similar to thermal burns of I, II, IIIA degrees with a predominant lesion of the upper and lower extremities.
2. Treatment of patients with photochemical dermatitis due to contact with hogweed juice should be carried out jointly by toxicologists and combustiologists in a multidisciplinary hospital.
3. The complex of therapeutic measures for the development of photochemical dermatitis as a result of contact with hogweed juice should include antihistamine, analgesic, detoxification, hormonal and antibacterial therapy, if indicated, as well as local treatment of affected skin surfaces according to algorithms for treating thermal lesions.

REFERENCES

1. Satsyperova IF. *Borshcheviki flory SSSR – novye kormovye rasteniya: Perspektivy ispol'zovaniya v narodnom khozyaystve*. Leningrad: Nauka Publ.; 1984. (In Russ.)
2. Tkachenko KG. *Heracleum L. Genus – Economic Plants. Bulletin of Udmurt University. Series Biology. Earth Sciences*. 2014;(4):27–33. (In Russ.)
3. Luneva NN. *Heracleum Sosnowskyi in Russia: Present Status and Relevance of Its Fastest Suppression. Plant Protection News*. 2013;(1):29–43. (In Russ.)
4. Romanovskiy AV, Pesnya DS. Toksikologicheskie issledovaniya borshchevika Sos-novskogo. In: *Aktual'nye problemy biologii i ekologii: materialy dokl. XXI Vseros. mo-lodezh. nauch. konf., posvyashch. 70-letiyu A.I. Taskaeva*. Syktyvkar; 2014. 299–303. (In Russ.) Available at: http://proborshev.ru/wp-content/uploads/2017/09/RomanovskiyAV_PesnyaDS_2014.pdf [Accessed 30 Oct, 2020]
5. *Dannye Ministerstva zdravookhraneniya Respubliki Komi o kolichestve ob-rashcheniy v meditsinskie uchrezhdeniya s povrezhdeniyami, poluchennymi v rezul'tate kontaktov s borshchevikom Sosnovskogo, a takzhe stepeni tyazhesti povrezhdeniy za peri-od s 2015 po 2017 gody (Otvet Minzdrava Respubliki Komi ot 28.05.2018 g.)*. (In Russ.) Available at: http://proborshev.ru/wp-content/uploads/2018/06/Otvet-Minzdrav-RK_2018.pdf [Accessed 30 Oct, 2020]
6. Afonin AN, Luneva NN, Li YuS, Kotsareva NV. Ecological-Geographical Analysis of Distribution Pattern and Occurrence of Cow-Parsnip (*Heracleum Sosnowskyi* Manden) With Respect to Area Aridity and Its Mapping in European Russia. *Russian Journal of Ecology*. 2017;48(1):86–89.
7. Dal'ke IV, Chadin IF, Zakhoshy IG, Malyshev RV, Golovko TK. Borshchevik Sos-novskogo — invazivnyy vid v agroklimaticheskoy zone Respubliki Komi. In: *Problemy sokhraneniya biologicheskogo raznoobraziya i ispol'zovaniya biologicheskikh resursov: materialy II-y Mezhdunar. nauch.-prakt. konf., (Minsk, Belarus, 22–26 oktyabrya 2012 g.)*. Minsk; 2012. 440–443. (In Russ.) Available at: http://proborshev.ru/wp-content/uploads/2017/09/Dalke_IV%2C%20Chadin_IF_Minsk_2012.PDF [Accessed 30 Oct, 2020].
8. Naumov SYu. Gigantskie borshcheviki v Krymu: *Heracleum mantegazzianum* vmesto *H. Pubescens*. *Doklady TSKhA (Ros. gos. agrar. un-t - MSKhA im. K. A. Timiryazeva)*. 2011; 283(Pt. 1): 606–610. (In Russ.)
9. Pesnya DS, Serov DA, Vakorin SA, Prokhorova IM. Research of the Toxic, Mitosis Mod-ifying And Mutagen Effect of *Heracleum Sosnowskyi*. *Yaroslavl Pedagogical Bulletin*. 2011; 3(4): 93–98. (In Russ.)
10. Rogozhnikova DR, Abramova LM. Some Evidence on Biology of *Heracleum Sosnowskyi* Manden in Bashkortostan. *Izvestiya Ufimskogo Nauchnogo Tsentra RAN*. 2018;(3):94–98. (In Russ.) <http://doi.org/10.31040/2222-8349-2018-0-3-94-98>
11. Rutman VV, Kantor GYa. Razrabotka komp'yuternoy programmy dlya identifikatsii i borshchevika Sosnovskogo po aerofotosnimku. In: *Biodiagnostika sostoyaniya prirodnkh i prirodno-tekhnogennykh sistem: materialy KhIV Vseros. nauch.-prakt. konf. c mezhdunar. uch.* Kirov; 2016. 183–185. (In Russ.)

12. Tkachenko KG, Krasnov AA. Heracleum Sosnowskyi: an Environmental Problem or a Crop of the Future? (Review). *Byulleten' Botanicheskogo sada-instituta DVO RAN*. 2018;(20):1–22. (In Russ.) <http://doi.org/10.17581/bbgi2002>
13. Klepov I.D. Puzyristye dermatity ot lugovogo rasteniya borshchevika. *Vestnik Dermatologii i Venerologii*. 1960;(3):34. (In Russ.)
14. Vinokurov GI. O dermatite, vyzyvayemom rasteniyem sladkiy borshchevik. *Military Medical Journal*. 1965;(7):34. (In Russ.)
15. Komissarenko NF, Zoz IG, Chernobay VT, Kolesnikov VG. Kumaryny plodov borshchevikov i taksonomiya. *Biokhimiya*. 1961;26(6):980–983. (In Russ.)
16. Laman NA, Prokhorov VN. Sposoby ogranicheniya rasprostraneniya i iskoreneniya gi-gantskikh borshchevikov: sovremennoe sostoyanie problemy. *Botanika (issledovaniya): sb. nauch. trudov In-ta eksperimental'noy botaniki NAN Belarusi*. 2011; 40:469–489. (In Russ.)
17. Dalke IV, Chadin IF, Zakhosiy IG. Analysis of Management Activities on Control of Sosnowsky's Hogweed (Heracleum Sosnowskyi Manden.) Invasion on the Territory of the Russian Federation. *Russian Journal of Biological Invasions*. 2018;(3):44–61. (In Russ.)
18. Karimian-Teherani D, Kinacian T, Tanew A. Photoallergic contact dermatitis to Heracleum giganteum. *Photodermatology, Photoimmunology & Photomedicine*. 2007;24(2):99–101. PMID: 18353092. <https://doi.org/10.1111/j.1600-0781.2008.00346.x>
19. Mang R, Stege H, Krutmann J. Mechanisms of Phototoxic and Photoallergic Re-actions. In: Johansen J, Frosch P, Lepoittevin JP. (eds) *Contact Dermatitis*. Springer, Berlin, Heidelberg; 2011.Ch.6.97–104. https://doi.org/10.1007/978-3-642-03827-3_8
20. Simonova AY, Ilyashenko KK, Pidchenko NE, Potkhveriya MM. Fotokhimicheskie dermatity v rezul'tate kontakta s sokom borshchevika Sosnovskogo. *Moskovskaya meditsina*. 2019;6(34):91. (In Russ.)

Received on 25.02.2020

Review completed on 16.04.2020

Accepted on 30.06.2020